

# The effects of aqueous extracts prepared from the leaves of *Pistacia lentiscus* in experimental liver disease

Predrag Ljubuncic<sup>a</sup>, Hui Song<sup>a</sup>, Uri Cogan<sup>b</sup>, Hassan Azaizeh<sup>c</sup>, Arie Bomzon<sup>a,\*</sup>

<sup>a</sup> Department of Pharmacology, Bruce and Ruth Rappaport Faculty of Medicine, Technion—Israel Institute of Technology, P.O. Box 9649, Haifa 31096, Israel

<sup>b</sup> Faculty of Food Engineering and Biotechnology, Technion—Israel Institute of Technology, Haifa, Israel

<sup>c</sup> Research and Development Regional Center (affiliated with the University of Haifa, Haifa, Israel), the Galilee Society, Shefa Amr, Israel

Received 13 September 2004; received in revised form 10 February 2005; accepted 4 March 2005

Available online 22 April 2005

## Abstract

In a previous study, we identified *Pistacia lentiscus* was worthy for further laboratory evaluation because an aqueous extract of the plant suppressed iron-induced lipid peroxidation in rat liver homogenates without affecting mitochondrial respiration in cultured HepG2 and PC12 cells. The present study was undertaken to evaluate the efficacy of an aqueous extract prepared from the dried leaves of *Pistacia lentiscus* in a rat model of hepatic injury caused by the hepatotoxin, thioacetamide. We assessed the impact of daily dosing on biochemical and morphological indices and the extent of oxidative stress in the livers of healthy and thioacetamide-treated rats. In healthy rats, long-term administration of the extract induced hepatic fibrosis and an inflammatory response, mild cholestasis and depletion of reduced glutathione associated with an increase in its oxidized form. In thioacetamide-treated rats, long-term administration of extract aggravated the inflammatory and fibrotic and glutathione depleting responses without affecting the extent of lipid peroxidation. Although our previous *in vitro* study established that extracts prepared from the leaves of *Pistacia lentiscus* had antioxidant activity, this *in vivo* study establishes these extracts also contains hepatotoxins whose identity may be quite different from those compounds with antioxidant properties. The results of this study suggest complementing *in vitro* experiments with those involving animals are essential steps in establishing the safety of medicinal plants. Furthermore, these data confirm that complete reliance on data obtained using *in vitro* methodologies may lead to erroneous conclusions pertaining to the safety of phytopharmaceuticals.

© 2005 Elsevier Ireland Ltd. All rights reserved.

**Keywords:** *Pistacia lentiscus*; Traditional medicine; Liver disease; Hepatotoxicity; Oxidative stress

## 1. Introduction

*Pistacia lentiscus* L (Anacardiaceae) (Mastic), one of the many evergreen bushes found in the eastern Mediterranean region, has a long tradition in folk medicine dating from the times of the ancient Greeks (Palevitch and Yaniv, 2000). Its

**Abbreviations:** ALP, alkaline phosphatase; ALT, alanine aminotransferase; AST, aspartate aminotransferase; GSH, glutathione; GSSG, oxidized glutathione; HE, hemotoxylin–eosin; LDH, lactate dehydrogenase; M3T, Masson's trichrome; MDA, malondialdehyde; TAA, thioacetamide; TBARS, thiobarbituric acid reactive substances

\* Corresponding author. Tel.: +972 4 8295259; fax: +972 4 8524978.

E-mail address: [bomzon@tx.technion.ac.il](mailto:bomzon@tx.technion.ac.il) (A. Bomzon).

medicinal uses are diverse and decoctions of its aerial parts and/or resin are used to treat coughs, sore throats, eczema, stomach aches, kidney stones and jaundice (Palevitch and Yaniv, 2000). Independent ethnobotanical and ethnopharmacological surveys conducted recently in Israel, Jordan and the Palestinian area disclose its current use is limited to treating stomach aches, heartburn, jaundice and respiratory problems (Ali-Shtayeh et al., 2000; Lev and Amar, 2000; Lev and Amar, 2002; Said et al., 2002).

Laboratory investigations on the bioactivity of *Pistacia lentiscus* are few in number. In 2002, Janakat and Al Merie reported that a single dose of aqueous boiled and non-boiled decoctions prepared from the leaves of *Pistacia lentiscus*

blunted the effects of single intoxicating dose of the known hepatotoxin, carbon tetrachloride. In a previous study involving the screening for bioactivity of eight plants used in Arabic traditional medicine in Israel, we identified *Pistacia lentiscus* was worthy for further laboratory evaluation because it was almost as effective in suppressing iron-induced lipid peroxidation in rat liver homogenates as Trolox, the water soluble analog of vitamin E and did not adversely affect cell membrane integrity or suppress mitochondrial respiration in cultured HepG2 and PC12 cells (Ljubuncic et al., 2005).

Focusing on its use to ameliorate jaundice, ambiguity on the exact meaning of the term “jaundice” exists. Jaundice is a syndrome characterized by hyperbilirubinemia and deposition of the pigment in the skin, mucous membranes and sclera resulting in a yellow appearance of the individual. It is frequently seen in individuals suffering from various liver diseases, such as cholestatic liver disease, obstructive jaundice and acute hepatocellular injury due to toxins, viruses, bacteria and parasites. However, the syndrome is not restricted only to liver disease but can also be due to a hemolytic crisis due to accelerated destruction of red blood cells. In the absence of an unequivocal definition of the term “jaundice” in the ethnobotanical and ethnopharmacological surveys, we sense the term was used imprecisely to refer to liver disease without any explicit clue to its cause.

Against this background, the present study was undertaken to evaluate the efficacy of an aqueous extract prepared from the dried leaves of *Pistacia lentiscus* in a rat model of hepatic injury caused by thioacetamide (TAA). TAA is a hepatotoxin frequently used to induce hepatocellular injury and hepatic fibrosis in rats (Muller et al., 1988). Its long-term administration causes the development of cirrhosis associated with an increased extent of lipid peroxidation (Muller et al., 1991). Using these rats, we designed an animal experiment in which we could assess the impact of daily dosing of the extract of the plant on biochemical and morphological indices of chronic hepatic injury. The doses of extract were based on an estimate of the minimum and maximum quantities of active ingredient that could be absorbed daily when the plant is used in traditional Arab medicine to treat liver disease (Said et al., 2002). These data were compared to identical data collected from rats, which were not exposed to TAA but were treated with the plant extract only.

## 2. Materials and methods

### 2.1. Ethical statement

The use of animals and the experimental protocols to which they were subjected were approved by the Committee for the Supervision of Animal Experimentation, Technion—Israel Institute of Technology, Haifa, Israel (approval # IL/11/02/2000).

### 2.2. Plant collection

Fresh leaves from *Pistacia lentiscus* (# RDC 1089; Said et al., 2002) were collected from wild bushes growing in the Eilaboun area of the Galilee region, Israel during the summer (June–August). The leaves were dried for 7–10 days in the shade at environmental temperatures (30–38 °C daytime). The dried leaves were then ground and the ground product was stored in cloth bags at 5 °C until transfer to the laboratory for preparation of dried aqueous extract.

### 2.3. Preparation of the dried aqueous extract

The method for preparing aqueous extracts from dried leaves has been already described (Ljubuncic et al., 2005). Briefly, dried leaves material (25 g) was stirred in 250 ml of distilled water for 15 min at 90 °C followed by rapid filtration through four layers of gauze and then by a more delicate filtration through Whatman filter paper #1. The resulting filtrate was frozen and freeze-dried. The yield of the powder was ~16% (w/w). The powder was stored at –18 °C in a desiccant until required.

### 2.4. Animals

Sixty-five male Sprague–Dawley rats weighing between 120 and 130 g were randomly divided into six groups. The rats were housed in a controlled environment (21 ± 1 °C, 40–60% humidity and 20 air changes per hour with a 12-h light:12-h dark cycle) with free access to food and water. Group 1 rats ( $n=9$ ) were gavaged daily for 5 weeks with 1 ml tap water; Group 2 rats ( $n=10$ ) were gavaged daily for 5 weeks with 15 mg/kg aqueous extract of *Pistacia lentiscus* in a 1 ml bolus; Group 3 rats ( $n=10$ ) were gavaged daily for 5 weeks with 75 mg/kg aqueous extract of *Pistacia lentiscus* in a 1 ml bolus; Group 4 rats ( $n=12$ ) were injected intraperitoneally twice weekly with 200 mg/kg TAA and gavaged daily for 5 weeks with 1 ml water; Group 5 rats ( $n=12$ ) were injected intraperitoneally twice weekly with 200 mg/kg TAA and gavaged daily for 5 weeks with 15 mg/kg aqueous extract of *Pistacia lentiscus* in a 1 ml bolus; and Group 6 rats ( $n=12$ ) were injected intraperitoneally twice weekly with 200 mg/kg TAA and gavaged daily for 5 weeks with 75 mg/kg aqueous extract of *Pistacia lentiscus* in a 1 ml bolus. The aqueous extracts were prepared daily from the freeze-dried powder.

At the end of the 5 weeks treatment period, the rats were anesthetized with pentobarbitone sodium (35 mg/kg). The abdomen and thoracic cavity was opened and the lower abdominal aorta exposed. Any rat displaying macroscopic evidence of pathology in organs, other than the liver, was excluded. Through an aortic 21G needle puncture, approximately 10 ml of arterial blood was withdrawn for determination of plasma glutathione (GSH) levels (described later) and standard serum indices of liver function. For serum assessment of liver function, the sample was allowed to clot,

centrifuged and the serum sample sent to the clinical laboratories of the Carmel Medical Center, Haifa to determine the activities of alanine aminotransferase (ALT), aspartate aminotransferase (AST) and alkaline phosphatase (ALP), together with total bilirubin levels using an autoanalyzer. The livers were excised, weighed and kept for determination of histological assessment of hepatic pathology and determination of the extent of lipid peroxidation. For liver pathology, a small sample of liver was preserved in isotonic formalin for histological examination (described later). The remainders of the individual livers were stored at  $-70^{\circ}\text{C}$  until required for determination of the extent of lipid peroxidation (described later).

### 2.5. Determination of plasma glutathione (GSH) levels

The determination of plasma GSH levels using GSH reductase was done according to the method described by Adams et al. (1983) with immediate acidification of plasma after blood centrifugation (3000 rpm for 5 min) to prevent spontaneous oxidation of GSH (50  $\mu\text{l}$  50% 5-sulfosalicylic acid/1 ml plasma). The acidified plasma samples were frozen at  $-70^{\circ}\text{C}$  for a maximum of 3 weeks. Before the determination of GSH, the sample was thawed and back-titrated to pH 7 with 0.2 mol/L NaOH. Two separate measurements were performed: the total plasma GSH and the oxidized form (GSSG). The reduced plasma GSH level was calculated as the difference between total GSH and the oxidized form. Total plasma GSH concentration was determined using 10 mmol/L 5,5'-dithio-bis-2-nitrobenzoic acid, after reduction of the GSSG by GSSG reductase (derived from Baker's yeast, Sigma Chemical Corp, St. Louis, MO, USA). The resulting amount of GSH was determined from a standard curve (0–2.5 nmol GSSG), measured spectrophotometrically at 412 nm and expressed as a change in absorbance per minute during reduction with GSH reductase. To measure plasma GSSG content, alkylation of the SH groups of glutathione was carried out with freshly prepared 10 mmol/L *N*-ethylmaleimide (NEM). To avoid the adverse effects of excess NEM on the enzymatic reaction used to determine GSSG levels, the excess NEM was removed by separation on a Sep-Pak (C18) column (Sigma Chemical Corp, St. Louis, MO, USA).

### 2.6. Histological evaluation of the liver

Sections of randomly selected fixed liver specimens from each group were embedded in paraffin and processed for light microscopy by staining individual sections with hematoxylin–eosin (HE) stain and Masson's trichrome (M3T) stain. Each section was subjectively scored by an independent observer for the extent of bile duct proliferation and fibrosis (M3T stain) with accompanying inflammation (HE stain) and duly graded on a scale between zero and four. Zero values were indicative of normal hepatic architecture in which there was no evidence of bile duct proliferation, inflammation and fibrosis whereas a score of 4 reflected a

gross disturbance of hepatic architecture typified by marked proliferation of the bile ducts with severe inflammation and a very conspicuous fibrotic response.

### 2.7. Preparation of crude liver homogenates and determination of malondialdehyde (MDA) content

The frozen livers were thawed, cut into small pieces by fine scissors, and then homogenized in ice-cold 100 mM sodium phosphate buffer, pH 7.4 with a Potter–Elvehjem glass homogenizer. The protein content of the individual liver homogenates was determined by the method described by Lowry et al. (1951) using crystalline bovine serum albumin (Sigma Chemical Corp, St. Louis, MO, USA) as the standard.

The assessment of the extent of hepatic lipid peroxidation relied on the determinations of MDA content in the crude liver homogenates. Duplicate determinations from each liver were made and the average of the two measurements was used in the subsequent statistical analysis of the data. MDA is an end-product of peroxidative decomposition of polyenoic fatty acids in the lipid peroxidation process and its accumulation in tissues is indicative of the extent of lipid peroxidation (Halliwell, 1991). Measurement of MDA relied on the thiobarbituric acid reactive substances (TBARS) assay (Draper and Hadley, 1990). TBARS reagent (1 ml) was added to a 0.5-ml aliquot of tissue homogenate and heated for 20 min at  $100^{\circ}\text{C}$ . The antioxidant, butylated hydroxytoluene, was added before heating of samples. After cooling on ice, the samples were centrifuged at  $840 \times g$  for 15 min and the absorbance of the supernatant was read at 532 nm. Sample blanks were prepared and assessed in the same way to correct for A532 contribution due to the sample. The TBARS results were expressed as MDA equivalents using 1,1,3,3-tetraethoxypropane as the standard.

### 2.8. Experimental design and statistical analysis

The sample size for each experiment was determined by power analysis arbitrarily set between 80 and 90% in order to detect an effect at the 5% significance level using Statmate™ version 1 (GraphPad Software Inc, San Diego, CA, USA). The data were analyzed by repeated measures one-way analysis of variance (ANOVA) with Dunnett's post test using Instat™ version 3 (GraphPad Software Inc, San Diego, CA, USA). All data are expressed as mean  $\pm$  standard error of the mean.

## 3. Results

During the 5 weeks treatment period, ten TAA-treated rats died presumably due to liver failure because we observed overt pathology only in this organ. Blood and liver samples were not collected from three rats at the time of sample collection due to evidence of pathology in other non-hepatic organs.

### 3.1. Body and liver weights

In water-treated rats, daily gavage with 15 mg/kg *Pistacia lentiscus* extract (Group 2) had no effect on body or liver weights compared to control water-treated rats (Group 1) (Fig. 1A and C). Daily gavage of 75 mg/kg extract caused non-significant reductions in body and liver weights (Group 3) compared to control water-treated rats (Fig. 1A and C). The body weights, but not liver weights, in all TAA-treated rats (Groups 4–6) were significantly lower ( $p < 0.001$ ) than the body weights of the control rats (Fig. 1A and C). This effect is more obvious in Fig. 1B which describes the changes in body weight over the 5 weeks observation period. The liver:body weight ratios of the TAA-treated rats were non-significantly higher than those determined in the TAA-untreated groups (Fig. 1D). From these data, we concluded that TAA-treated rats did not thrive as well as TAA-untreated rats, and this failure to thrive was probably due to TAA and not dosing with *Pistacia lentiscus* extract.

### 3.2. Serum indices of liver injury

Compared to control rats, TAA-treated rats had raised serum activities of ALT, AST and ALP and bilirubin levels (Fig. 2A–D). Treatment with *Pistacia lentiscus* extract in the water- and TAA-treated rats caused modest increases in serum bilirubin levels (Fig. 2). The increases in the activities of AST and ALT and the levels of bilirubin in the group of rats treated with 15 mg/kg extract was due to marked elevations in the serum activities of these enzymes and the serum levels of bilirubin in three of the eight rats.

### 3.3. Liver histopathology

In rats treated with *Pistacia lentiscus* extract (Groups 2 and 3), evidence of increased hepatic inflammation and fibrosis were observed (Fig. 3). TAA provoked an increase in hepatic inflammation and fibrosis both of which were aggravated by *Pistacia lentiscus* extract, even at the lower dose (Fig. 3).

### 3.4. Plasma glutathione levels

In the untreated TAA rats, total plasma glutathione levels were non-significantly reduced in rats treated with the low 15 mg/kg dose of *Pistacia lentiscus* extract (Fig. 4A). At the higher 75 mg/kg dose of the *Pistacia lentiscus* extract, total plasma glutathione levels were approximately half of those determined in the control rats (Fig. 4A). In TAA-treated rats, the total plasma glutathione levels were furthered by the plant lowered (Fig. 4A). These decrements in total glutathione levels were associated with reductions in the plasma levels of reduced glutathione and increases in the plasma levels of GSSG, resulting in rises in the glutathione redox state (Fig. 4B–D). Statistically significant correlations between shifts in individual plasma GSH study parameters and the individual serum indices of liver function were not detected. Overall, these observations indicate reduced GSH depletion is part of the hepatotoxic actions of TAA and *Pistacia lentiscus*.

### 3.5. Extent of hepatic lipid peroxidation

MDA levels were greater in liver homogenates prepared from TAA-treated rats than those measured in liver ho-

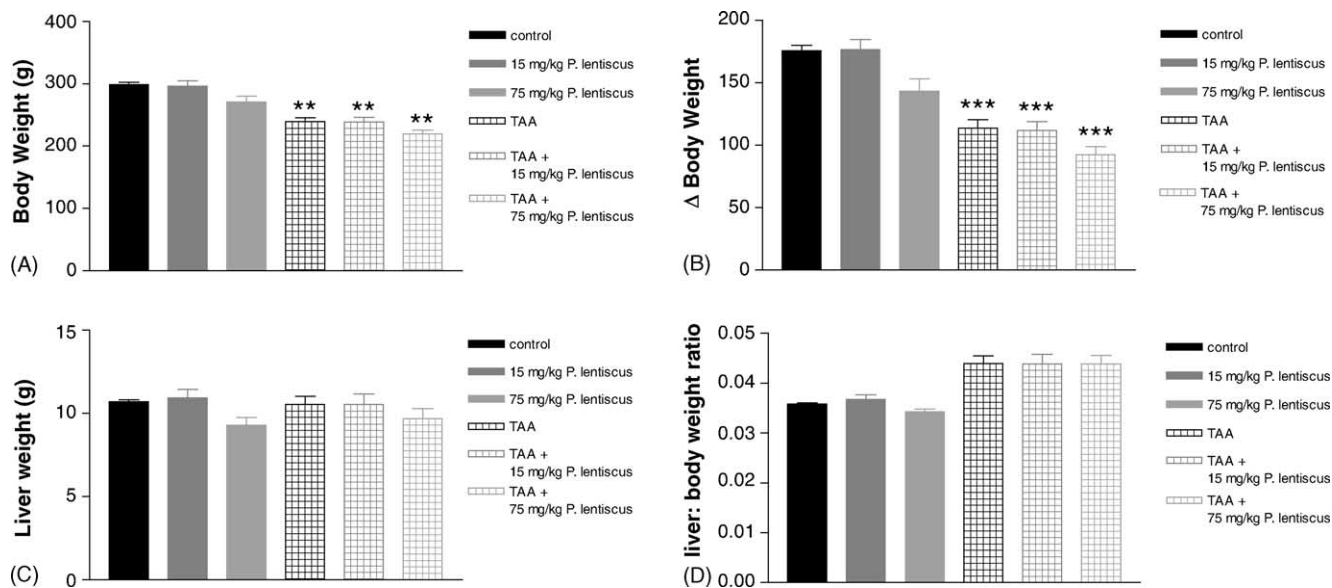


Fig. 1. The effect of daily oral dosing of 15 and 75 mg/kg water extract of *Pistacia lentiscus* for 5 weeks on the body and liver weights of water- and thioacetamide-treated rats. Data are presented as mean  $\pm$  standard error of the mean. \*\* $p < 0.01$ ; \*\*\* $p < 0.001$  represents the significance of the difference from water-treated rats. Sample size = 8–9.

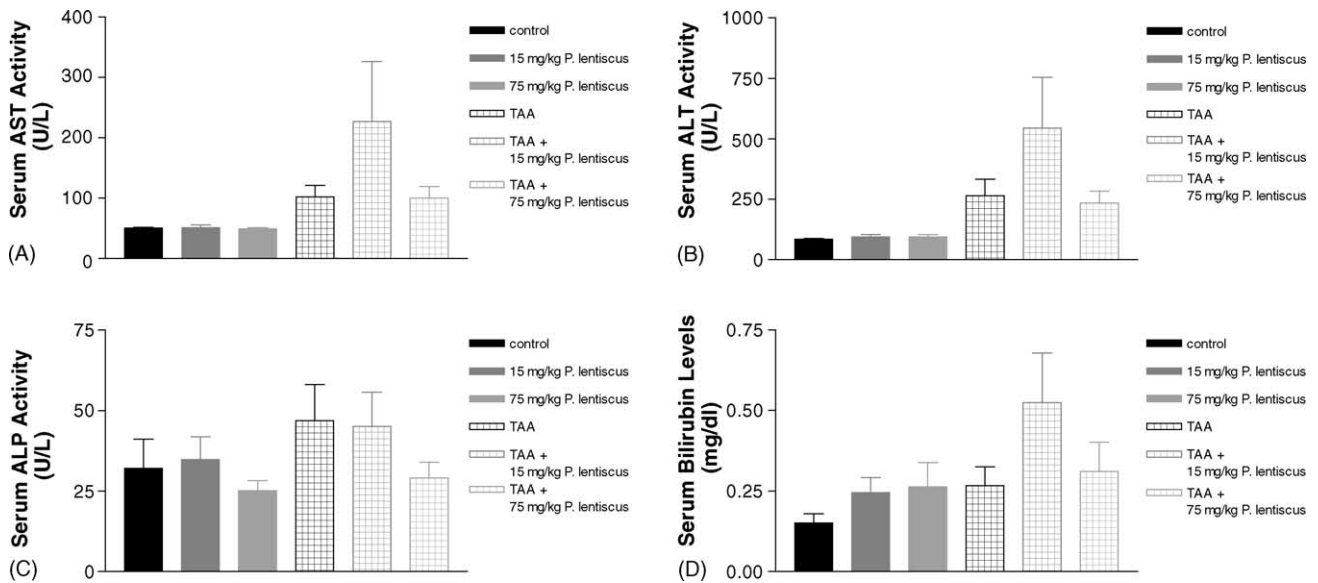


Fig. 2. The effect of daily oral dosing of 15 and 75 mg/kg water extract of *Pistacia lentiscus* for 5 weeks on the serum activities of AST, ALT and ALP and bilirubin levels in the serum of water- and thioacetamide-treated rats. Data are presented as mean  $\pm$  standard error of the mean. Sample size = 8–9.

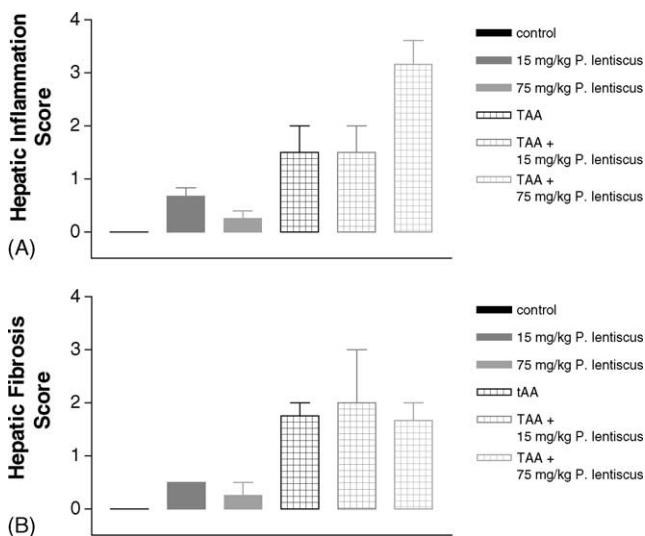


Fig. 3. The effect of daily oral dosing of 15 and 75 mg/kg water extract of *Pistacia lentiscus* for 5 weeks on the extent of inflammation and fibrosis in the livers of water- and thioacetamide-treated rats. Data are presented as mean  $\pm$  standard error of the mean. Sample size = 8–9.

mogenates from water-treated rats (Fig. 5). Administration of the plant extract at both doses in water-treated and TAA-treated rats did not alter the extent of lipid peroxidation (Fig. 5).

#### 4. Discussion

In our previous paper, we proposed further laboratory investigation on the bioactivity of *Pistacia lentiscus* extract was warranted because a water-soluble extract prepared from the leaves of *Pistacia lentiscus* was almost as effective as

Trolox, the water-soluble analog of vitamin E in suppressing iron-induced lipid peroxidation in rat liver homogenates (Ljubuncic et al., 2005). Accordingly, the present study was undertaken to evaluate the hepatoprotective efficacy of *Pistacia lentiscus* in a rat model of chronic liver disease in order to confirm this plant does indeed have a therapeutic benefit in liver disease. We found long-term administration of *Pistacia lentiscus* extract in healthy rats induced hepatic fibrosis and an inflammatory response, mild cholestasis, depletion of reduced GSH associated with an increase in its oxidized form. Collectively, these data indicate that water extracts of *Pistacia lentiscus* at doses used in the study are hepatotoxic. Furthermore, its hepatotoxic effects are seemingly dose-dependent.

We are only aware of one study in which the effect of *Pistacia lentiscus* has been evaluated in animal model of liver disease. In 2002, Janakat and Al Merie reported aqueous boiled and non-boiled decoctions prepared from the leaves of *Pistacia lentiscus* lowered the serum activities of ALP, ALT and AST and the level of bilirubin in rats given a single intoxicating dose of the hepatotoxin, carbon tetrachloride. From these results, they concluded a hepatoprotectant action of *Pistacia lentiscus* and added that the plant possessed therapeutic potential in the treatment of human hepatic jaundice. One of the obvious differences between our study and that of Janakat and Al Merie is the experimental design. In our study, the rats were treated daily for 5 weeks whereas Janakat and Al Merie (2002) only gave a single dose of a decoction of *Pistacia lentiscus*. We and others previously reported that *Pistacia lentiscus* has a high antioxidant potential established in vitro (Barotto et al., 2003; Ljubuncic et al., 2005). In addition to containing antioxidant flavonol glycosides that include myricetin and quercetin glycosides, the leaves of *Pistacia lentiscus* contain large amounts of gallic acid and galloyl derivatives (Romani et al., 2002). These compounds are also

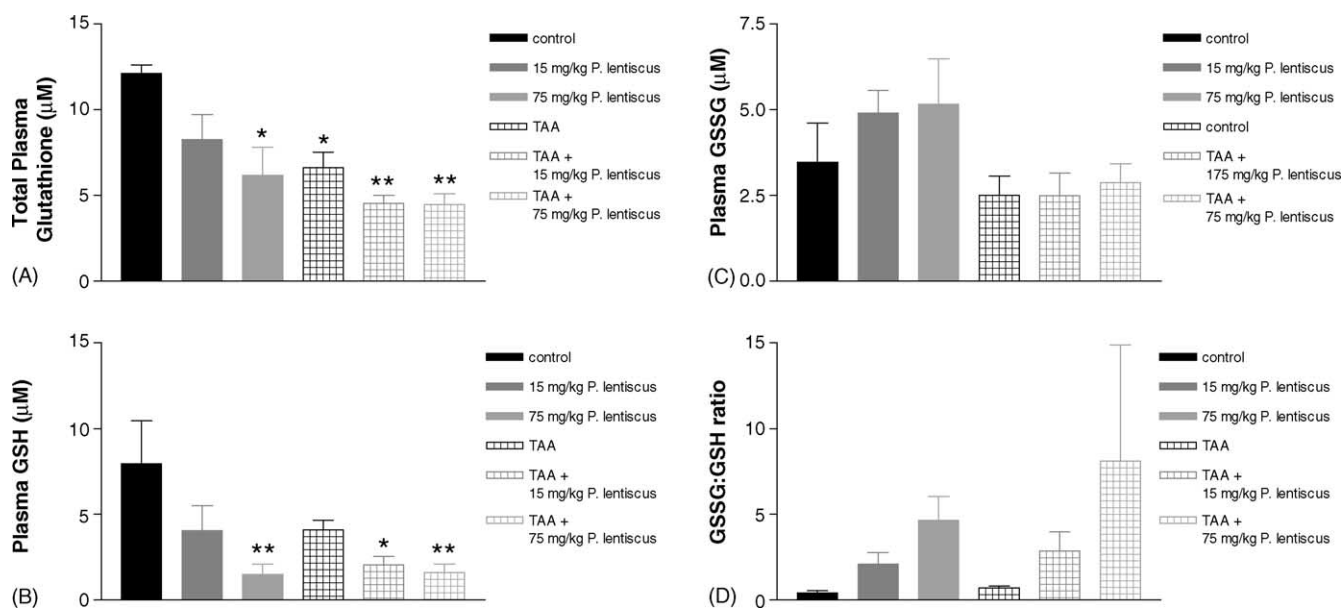


Fig. 4. The effect of daily oral dosing of 15 and 75 mg/kg water extract of *Pistacia lentiscus* for 5 weeks on GSH levels in the plasma of water-treated and thioacetamide-treated rats. Data are presented as mean  $\pm$  standard error of the mean. \* $p < 0.05$ ; \*\* $p < 0.01$  represents the significance of the difference from water-treated rats. Sample size = 8–9.

efficient antioxidants capable of scavenging hydroxyl radicals and effectively reducing the extent of oxidation of low-density lipoproteins (Barotto et al., 2003). Therefore, it is not unreasonable to assume that the widespread use of *Pistacia lentiscus* in traditional Arab medicine can be attributed to the content of these antioxidant phytochemicals.

Our in vitro studies also demonstrated that the leaves of *Pistacia lentiscus* may contain toxic phytochemical(s) (Ljubuncic et al., 2005). The results of this study confirm that this plant is hepatotoxic. This result contrasts the experimental findings of Janakat and Al Merie (2002) who reported that a single dose of a decoction of *Pistacia lentiscus* was beneficial. This effect is seemingly time-dependent because a single oral dose of the decoction was beneficial. This discrepancy obviously warrants further investigation. We know the leaves of *Pistacia lentiscus* contain condensed tannins that are proven hepatotoxins (Oelrichs et al., 1994; Decandia et al., 2000). Therefore, we can only speculate that long-term

treatment with *Pistacia lentiscus* could have induced hepatotoxicity due to the activity of these tannins.

TAA is a known hepatotoxin (Muller et al., 1988). Our data confirms its hepatotoxic action where we have shown that its biweekly administration for 5 weeks caused hepatic inflammation and fibrosis associated with an increase in GSH redox state and the extent of hepatic lipid peroxidation. Based upon our in vitro findings, we anticipated that water extracts of *Pistacia lentiscus* would be hepatoprotective and would thus ameliorate the hepatotoxic actions of TAA. In fact, we found the contrary in that administration of the plant aggravated the hepatotoxic actions of TAA. From our data on *Pistacia lentiscus* administration in healthy rats, we now are aware that these rats were exposed to, at least, two hepatotoxins.

Although we found evidence of increased inflammation, fibrosis and extent of lipid peroxidation with GSH depletion in the liver of TAA-treated rats dosed with *Pistacia lentiscus*, one needs to distinguish between TAA-induced and plant-induced phenomena. Our data in TAA-untreated rats indicates that the plant induces a mild inflammatory and fibrotic response with GSH depletion. We found no evidence of an increased extent of lipid peroxidation in the livers of these rats. In TAA-treated rats, all of the abovementioned phenomena were observed as well as an increased extent of lipid peroxidation. These effects can be attributed to the hepatotoxic actions of TAA. When TAA-treated rats were dosed with *Pistacia lentiscus* extract, the inflammatory and fibrotic and GSH depleting responses were aggravated but the extent of lipid peroxidation was unaffected. Therefore, one can conclude that water extracts of *Pistacia lentiscus* are hepatotoxic. Furthermore, we were unable to demonstrate that this plant does indeed possess an antioxidant ac-

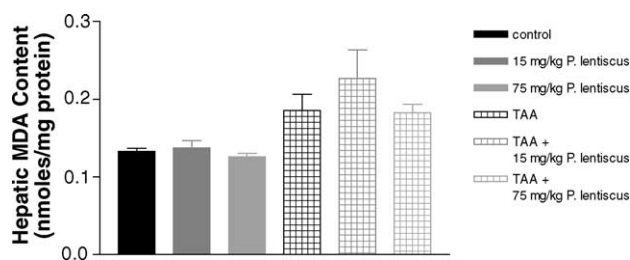


Fig. 5. The effect of daily oral dosing of 15 and 75 mg/kg water extract of *Pistacia lentiscus* for 5 weeks on hepatic MDA levels in the liver of water-treated and thioacetamide-treated rats. Data are presented as mean  $\pm$  standard error of the mean. Sample size = 8–9.

tion in vivo because we found dosing with *Pistacia lentiscus* did not reduce the increased extent of lipid peroxidation in livers of TAA-treated rats. However, these data do not eliminate the possibility that the hepatotoxic action of *Pistacia lentiscus* overwhelmed thereby masking any antioxidant activity.

Although our in vitro study established that water extracts of *Pistacia lentiscus* possessed bioactive compounds with antioxidant properties, the same study also hinted the plant had cytotoxic potential (Ljubuncic et al., 2005). This in vivo study confirms the presence of hepatotoxins in the plant whose identity may be quite different from those compounds with antioxidant properties. Hence, these data highlight an important principle when conducting research into the supposed beneficial actions of medicinal plants. Our observations from using both in vitro and in vivo techniques indicate the importance of the combined approach. Data obtained from in vitro experiments are useful for identifying a mechanism of action of plant extracts and giving an indication of their cytotoxic potential. The results of this study suggest that complementing in vitro experiments with those involving animals are essential steps in establishing the safety of medicinal plants and validating the supposed mechanism of action. Furthermore, these data confirm that complete reliance on data using in vitro methodologies may lead to erroneous conclusions pertaining to the safety of phytopharmaceuticals.

## 5. Conclusions

Aqueous extracts prepared from the leaves of *Pistacia lentiscus* are commonly used to treat jaundice in Arab traditional medicine in Israel, Jordan and the Palestinian areas. The results of this study show that this plant is hepatotoxic when administered daily for 5 weeks. This study also emphasizes the usefulness of a dual strategy involving in vitro and in vivo experiments on medicinal plants commonly used in traditional medicine whose safety has not been yet sufficiently established to distinguish between beneficial and adverse effects.

## Acknowledgements

The authors wish to thank Mr. Jonathan Ritter for help in collecting the plant. This research was supported by grants from the Ministry of Science and Technology, Jerusalem, Israel, the Center for Absorption in Science of the Ministry of Immigrant Absorption and the Committee for Planning and Budgeting of the Council for Higher Education under the framework of the KAMEA Program and the Technion

Vice-President Research Fund for Promotion for Research at the Technion.

## References

- Adams, J.D., Lanterberg, B.H., Mitchell, J.R., 1983. Plasma glutathione and glutathione disulfide in the rat: regulation and response to oxidative stress. *Journal of Pharmacology and Experimental Therapeutics* 227, 749–754.
- Ali-Shtayeh, M.S., Yaniv, Z., Mahajna, J., 2000. Ethnobotanical survey in the Palestinian area: a classification of the healing potential of medicinal plants. *Journal of Ethnopharmacology* 73, 221–232.
- Barotto, M.C., Tattini, M., Galardi, C., Pinelli, P., Romani, A., Visioli, F., Basosi, R., Pogni, R., 2003. Antioxidant activity of galloyl quinic derivatives isolated from *P. lentiscus* leaves. *Free Radical Research* 37, 405–412.
- Decandia, M., Sitzia, M., Cabiddu, A., Kababya, D., Molle, G., 2000. The use of polyethylene glycol to reduce the anti-nutritional effects of tannins in goats fed woody species. *Small Ruminant Research: The Journal of the International Goat Association* 38, 157–164.
- Draper, H.H., Hadley, M., 1990. Malondialdehyde determination as an index of lipid peroxidation. *Methods in Enzymology* 186, 421–431.
- Halliwell, B., 1991. Reactive oxygen species in living systems: source, biochemistry, and role in human disease. *American Journal of Medicine* 91, 14s–22s.
- Janakat, S., Al Merie, H., 2002. Evaluation of hepatoprotective effect of *Pistacia lentiscus*, *Phillyrea latifolia* and *Nicotiana glauca*. *Journal of Ethnopharmacology* 83, 135–138.
- Lev, E., Amar, Z., 2000. Ethnopharmacological survey of traditional drugs sold in Israel at the end of the 20th century. *Journal of Ethnopharmacology* 72, 191–205.
- Lev, E., Amar, Z., 2002. Ethnopharmacological survey of traditional drugs sold in the Kingdom of Jordan. *Journal of Ethnopharmacology* 82, 131–145.
- Ljubuncic, P., Cogan, U., Portnaya, I., Azaizeh, H., Said, O., Bomzon, A., 2005. Antioxidant activity and cytotoxicity of eight plants used in traditional Arab medicine in Israel. *Journal of Ethnopharmacology* 99, 43–47.
- Lowry, O.H., Rosebrough, N.J., Farr, A.L., Randall, R.J., 1951. Protein measurement with the Folin phenol reagent. *Journal of Biological Chemistry* 193, 265–275.
- Muller, A., Machnik, F., Zimmermann, T., Schubert, H., 1988. Thioacetamide-induced cirrhosis-like liver lesions in rats—usefulness and reliability of this animal model. *Experimental Pathology* 34, 236.
- Muller, D., Sommer, M., Kretzchmar, M., Zimmerman, T., Buko, V.U., Lukivskaya, O., Dargel, R., 1991. Lipid peroxidation in thioacetamide-induced macronodular rat liver cirrhosis. *Archives of Toxicology* 65, 199–203.
- Oelrichs, P.B., Pearce, C.M., Zhu, J., Filippich, L.J., 1994. Isolation and structure determination of terminalin A toxic condensed tannin from *Terminalia oblongata*. *Natural Toxins* 2, 144–150.
- Palevitch, D., Yaniv, Z., 2000. *Medicinal Plants of the Holy Land*. Modan Publishing House, Tel Aviv, Israel.
- Romani, A., Pinelli, P., Galardi, C., Mulinacci, N., Tattini, M., 2002. Identification and quantification of galloyl derivatives, flavonoid glycosides and anthocyanins in leaves of *Pistacia lentiscus* L. *Phytochemical Analysis* 13, 79–86.
- Said, O., Khalil, K., Fulder, S., Azaizeh, H., 2002. Ethnopharmacological survey of medicinal herbs in Israel, the Golan Heights and the West Bank region. *Journal of Ethnopharmacology* 83, 251–265.